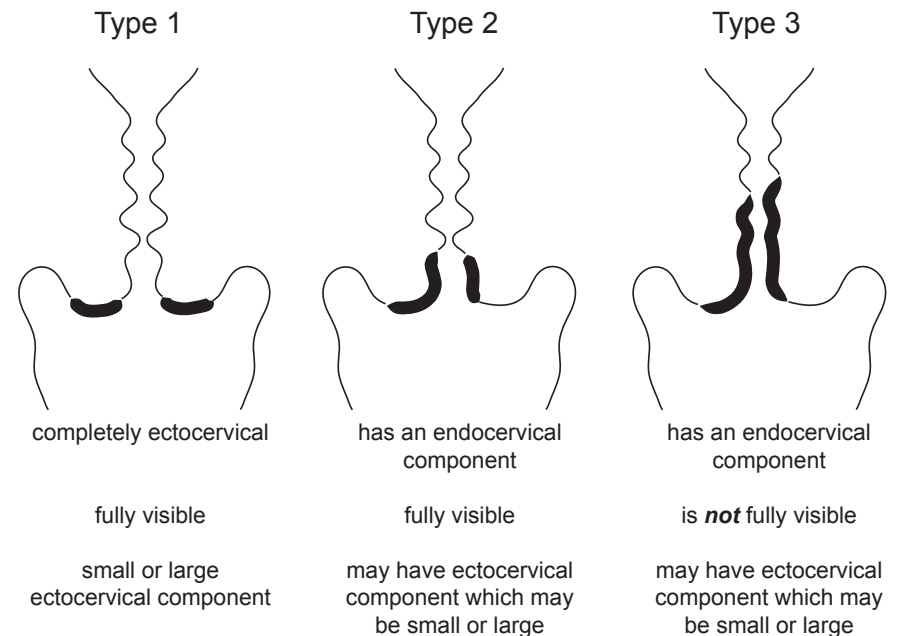
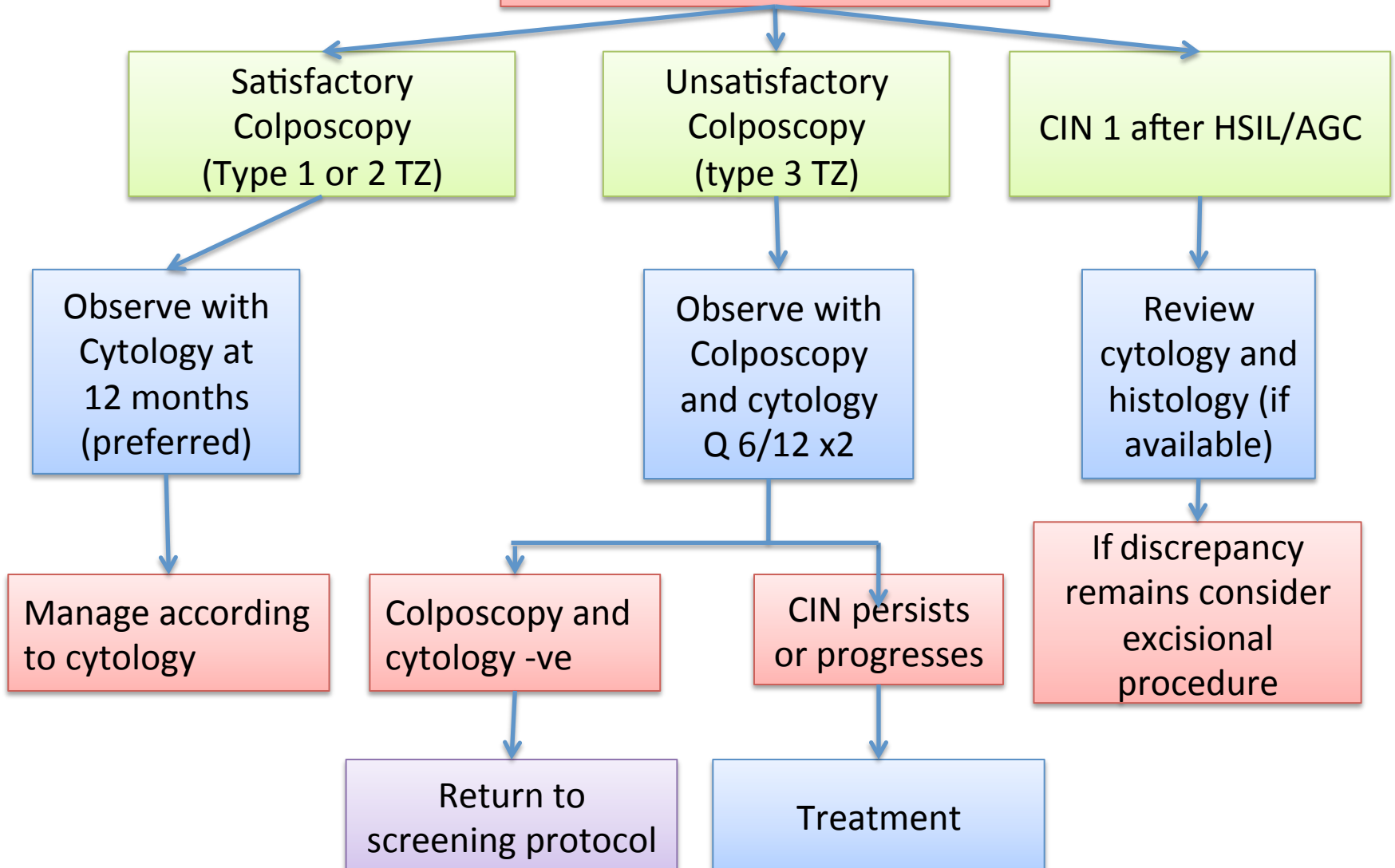


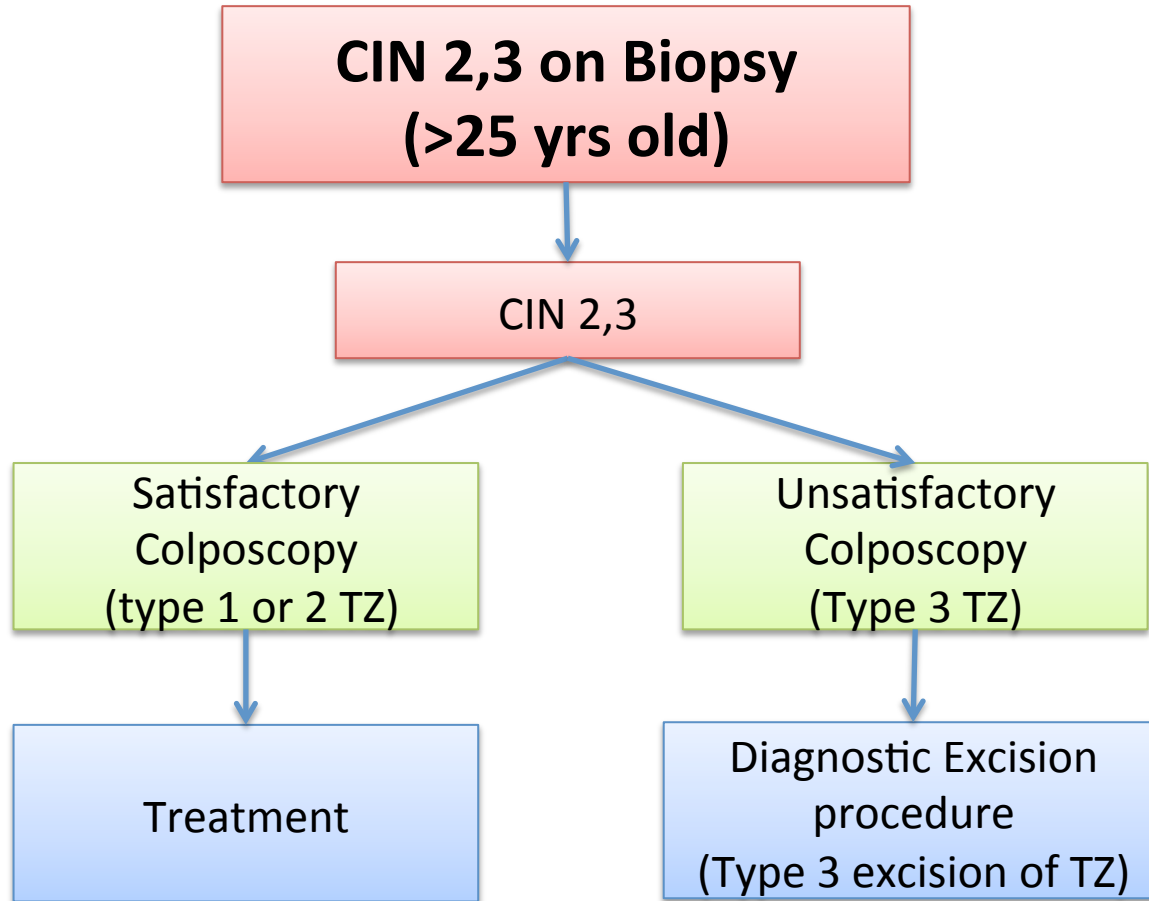
- Terminology in guidelines based on the 2011 IFCCPC nomenclature<sup>1</sup>
- Satisfactory colposcopy is defined as adequate visualization of cervix and a SCJ being fully visible, i.e. a type 1 or 2 TZ

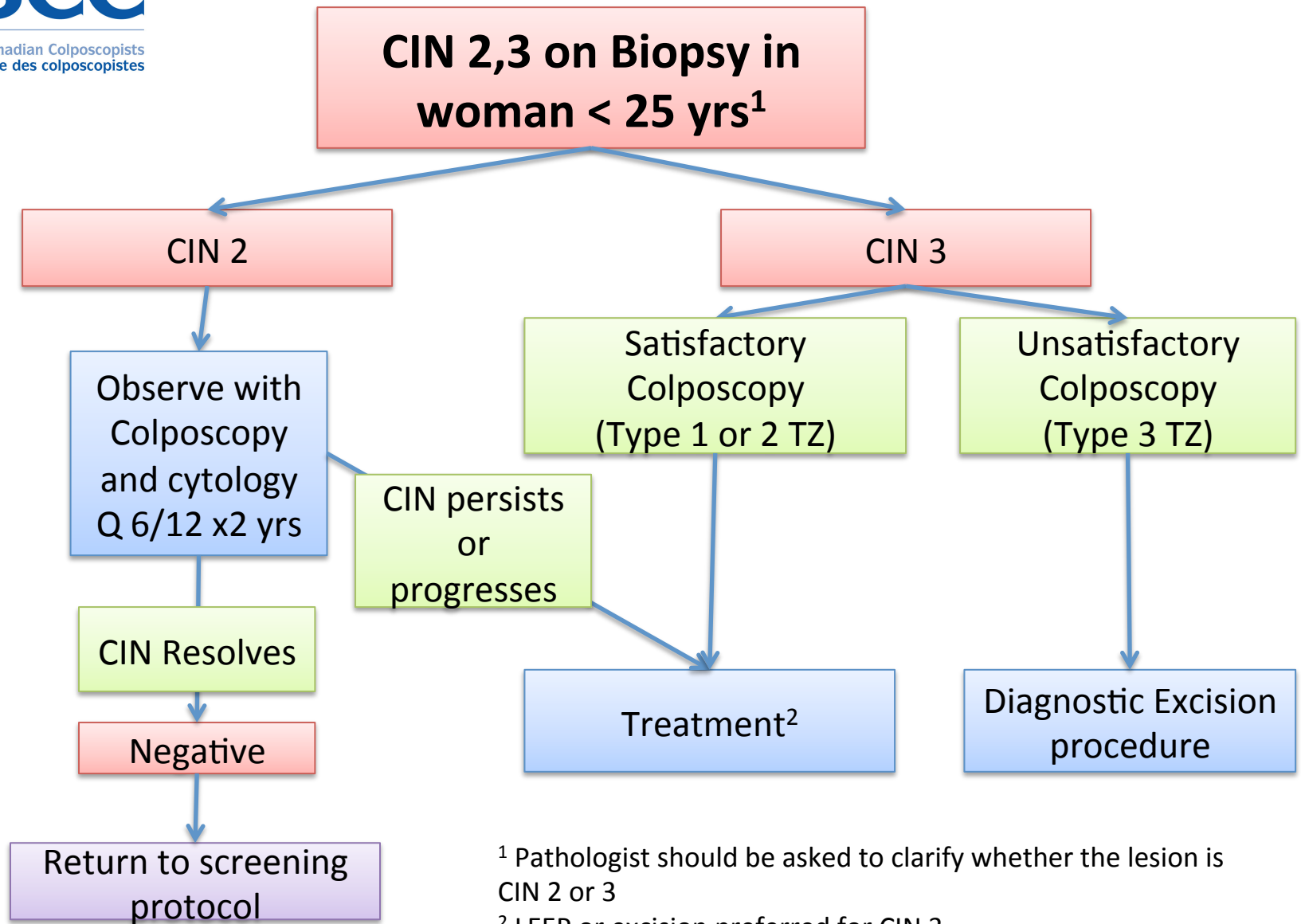


<sup>1</sup> Bornstein J et al Obstet Gynecol. 2012 Jul;120(1):166-72

# CIN 1 on Biopsy or ECC



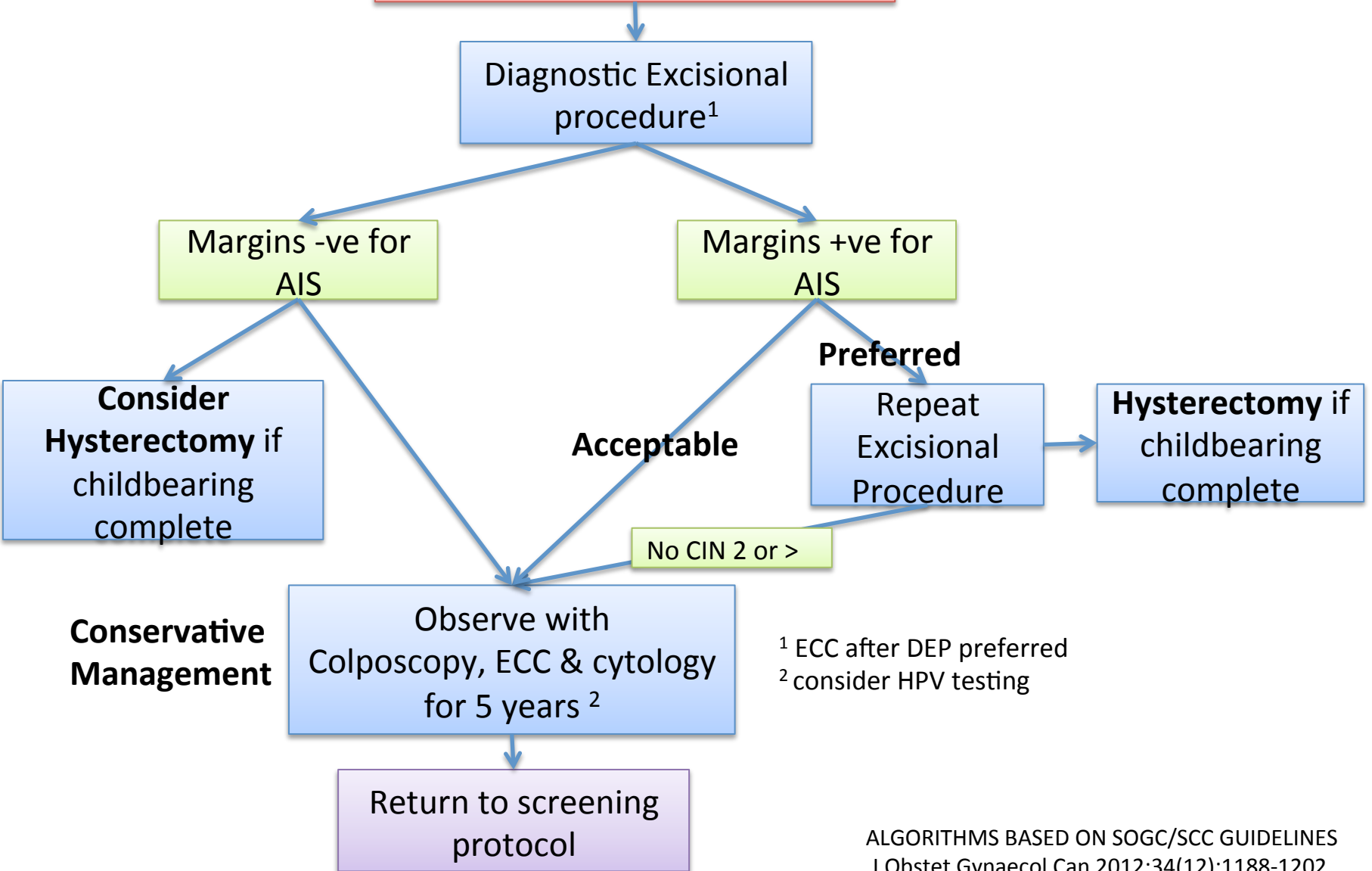




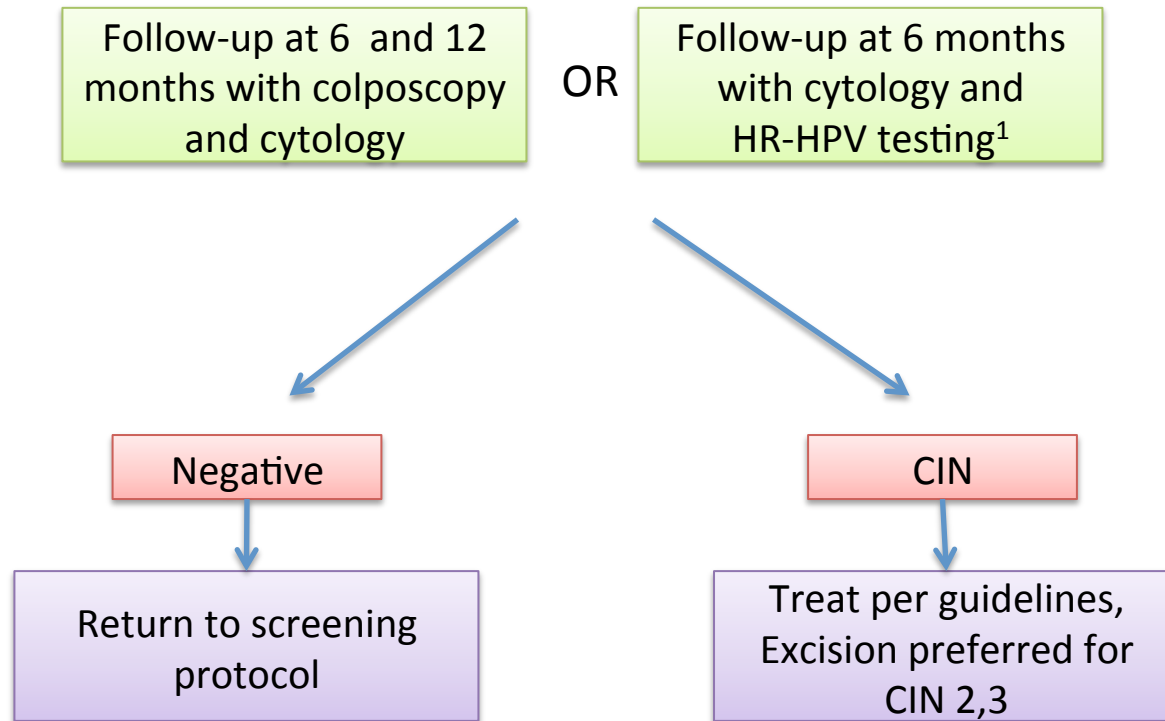
<sup>1</sup> Pathologist should be asked to clarify whether the lesion is CIN 2 or 3

<sup>2</sup> LEEP or excision preferred for CIN 3

# AIS on Biopsy



## Follow-up Post treatment for CIN



<sup>1</sup> HPV testing for high risk HPV